European Heart Journal - Cardiovascular Imaging Advance Access published May 29, 2013

European Heart Journal – Cardiovascular Imaging
doi:10.1093/ehjci/jet052

Very late stent thrombosis related to incomplete neointimal coverage or neoatherosclerotic plaque rupture identified by optical coherence tomography imaging

Nicolas Amabile[1]*, Géraud Souteyrand[2,3], Said Ghostine[1], Nicolas Combaret[2,3], Michel S. Slama[4], Nicolas Barber-Chamoux[2,3], Pascal Motreff[2,3], and Christophe Caussin[1]

[1]Department of Cardiology, Centre Marie Lannelongue, 133 avenue de la Resistance, Le Plessis-Robinson 92350, France; [2]Department of Cardiology, Clermont-Ferrand University Hospital, Clermont-Ferrand, France; [3]ISIT, CNRS, UMR6284, Auvergne University, Clermont-Ferrand, France; and [4]Department of Cardiology, Antoine Béclère Hospital, Clamart, France

Received 27 December 2012; accepted after revision 13 March 2013

Aims Recent data have reported that neoatherosclerosis could develop long after stent implantation and lead to subsequent rupture and acute coronary syndrome (ACS). We sought to identify the presence of in-stent neoatheroma (ISNA) in patients with very late stent thrombosis (VLST) using optical coherence tomography (OCT).

Methods and results All patients from two catheterization centres who presented with ACS related to VLST underwent a standard coronary angiography and intra-coronary OCT. ISNA was defined as the combination of diffuse neointimal proliferation, lipid-laden intima with plaque organization, and fibrous cap rupture with no evidence of an uncovered strut.

Out of 2139 ACS patients, 20 presented with definite VLST, including 10 with evidence of ISNA lesions, detected using OCT. The mean delay between initial percutaneous coronary intervention and VLST was longer in the ISNA patients compared with non-ISNA patients (10.5 ± 1.6 vs. 4.0 ± 0.6 years, $P = 0.003$). The mean LDL-cholesterol tended to be higher in ISNA patients compared with non-ISNA patients. OCT analysis revealed significantly thicker neointimal coverage as well as a lower number of uncovered struts in ISNA lesions compared with the other patients. LDL-cholesterol levels were correlated with the average neointima thickness (Spearman's rho $= 0.46$, $P = 0.04$). All the ISNA lesions were treated through initial thrombectomy followed by redo stenting in nine patients.

Conclusion Our data show that ISNA is frequent in patients with VLST. These results suggest that OCT imaging is helpful in identifying the underlying mechanisms of VLST and, therefore, in the clinical decision-making process.

Keywords Acute coronary syndromes • Stent thrombosis • Optical coherence tomography imaging

Introduction

Since its introduction in the late 1980s, the development of percutaneous coronary intervention (PCI) with stent implantation has dramatically changed the management of patients with stable and unstable coronary artery disease.[1] Despite improvements in device design, anti-platelet therapy (APT), and clinical results, in-stent restenosis and thrombosis remain two drawbacks of this technique. In-stent restenosis was initially considered as a stable process, with an early peak in intimal hyperplasia (IH) followed by a quiescent period beginning from 6 months to 1 year after stent implantation.[2] However, the most recent pathological and clinical data highlight that the phenomenon underlying restenosis continues to develop over many years after stent implantation

* Corresponding author. Tel: +33 1 40 94 86 54; Fax: +33 1 40 94 85 49, Email: n.amabile@ccml.fr

and may occur in drug-eluting stents (DESs) as well as bare-metal stents (BMS).[3,4] Ultimately, IH may result in neoatherosclerosis that associates peri-strut foamy macrophage clusters with or without calcification, fibroatheromas, and thin-cap fibroatheromas.[3,5] Although incomplete stent apposition on the vascular wall as well as incomplete lesion coverage have been identified as major determinants of late stent thrombosis (LST/stent thrombosis occurring between 30 Days and 1 year after stent placement) and very late stent thrombosis (VLST/stent thrombosis occurring >1 year following stent placement),[6,7] neoatherosclerotic plaque rupture is now acknowledged as a potential contributing factor.[8] Whereas standard coronary luminography cannot identify these lesions, they can be detected through the use of intra-coronary imaging techniques, including optical coherence tomography (OCT).[9,10] Previous studies have described OCT's capability and efficiency in identifying neoatherosclerosis within BMS[5,11] or DES.[12] However, the mechanisms involved in the progression of this phenomenon remain poorly understood.[8]

Using OCT, we sought to investigate the incidence and characteristics of in-stent neoatherosclerotic (ISNA) lesions among a cohort of 'real-world' patients with VLST.

Methods

Patient selection

This observational study is based on data collected from our registry including patients from two catheterization centres (Centre Marie Lannelongue and Gabriel Montpied University Hospital Center). Patients who were referred with acute coronary syndromes [ACSs; with ST elevation myocardial infarction (STEMI) or non-ST elevation myocardial infarction (NSTEMI)] were prospectively screened for the presence of definite VLST, as previously defined by the Academic Research Consortium (ARC): 'symptoms suggestive of an acute coronary syndrome and angiographic or pathologic confirmation of stent thrombosis, occurring over twelve months after stent implantation'.[6]

Standard clinical and biological characteristics were established, including fasting LDL-cholesterol measurement. The creatine phosphokinase peak value was determined according to consecutive measurements on blood samples. The APT regimen of the patients, the date and type of stent implanted were retrospectively obtained by interviewing the cardiologists in charge of the patients. Our local Ethics Committee approved the study and informed consent was obtained.

ACS medical management and coronary angiography analysis

All patients included in the study were treated in accordance with the European Society of Cardiology guidelines for the management of patients with STEMI and NSTEMI.[13] Patients were routinely treated with aspirin, clopidogrel or prasugrel, abciximab, unfractionated, or low-weight heparin according to current international guidelines.[13]

Two operators retrospectively reviewed coronary angiography and analysed pre- and post-thrombectomy culprit lesion characteristics, including the antegrade angiographic flow in the culprit vessel according to the Thrombolysis in myocardial infarction criteria, collateral filling of the culprit vessel according to the Rentrop classification,[14] and calculation of the degree of stenosis (before and after thrombectomy) using a dedicated quantitative coronary angiography (QCA) software (Centricity CA1000/GE Healthcare, Buc, France).

PCI and FD-OCT images acquisition

All procedures were performed through radial access. PCI was performed with a 6 Fr guiding catheter in all patients. A 0.014-inch guide wire was placed distally in the target vessel. Thrombo-aspiration was first performed using a manual thrombectomy device (Eliminate, TERUMO) in patients with initial TIMI flow <2 in order to obtain an antegrade TIMI flow = 3. Frequency domain (FD)-OCT images were then acquired with a commercially available system (C7 System; LightLab Imaging, Inc./St Jude Medical, Westford, MA, USA) after the OCT catheter (C7 Dragonfly; LightLab Imaging, Inc./St Jude Medical) was advanced to the distal end of the target lesion. The first FD-OCT run was conducted before either direct stent implantation or balloon predilatation (pre-PCI run). The entire length of the target area was scanned using the integrated automated pullback device at 20 mm/s. During image acquisition, the coronary blood flow was replaced by continuous flushing of contrast media directly from the guiding catheter at a rate of 4 mL/s with a power injector in order to create a virtually blood-free environment.

After OCT imaging, the operator was given the choice between one of the following pre-defined strategies: (i) immediate culprit lesion stenting; (ii) immediate culprit lesion treatment with balloon angioplasty alone; (iii) medical treatment with anticoagulant therapy and subsequent OCT control with *ad hoc* PCI.

FD-OCT images analysis

All the images were recorded digitally, stored and each frame (0.2 mm) read by two independent investigators, allowing systematic analysis at 1 mm intervals. Offline analysis was performed with proprietary software (Lightlab, Imaging, Inc./St Jude Medical) after confirming calibration settings of the Z-offset.

The outlines of stent and lumen were drawn for area measurements: the stent area (SA) and the intra-stent lumen area (intra-stent area) were calculated for each interval within the stent. Neointima was the tissue between the luminal border (with the exclusion of the thrombus) and the inner border of the struts. An uncovered strut was defined as a strut of measured neointimal thickness equal to 0 μm.[15] A malapposed strut was a strut with a measured distance between its surface and the adjacent vessel surface greater than the strut thickness for BMS or greater than the sum of the thickness of the strut plus polymer for DES.[15] Neointimal thickness (per strut) and area (per cross-sectional area) were calculated as previously reported.[16] The lipid-laden intima was defined as a poor signal region with diffuse borders.[10] Intimal vessels (or micro-channels) were defined as poor signal voids that are sharply delineated and can be followed in multiple contiguous frames; calcifications zones were defined as a poor signal or heterogeneous regions with a sharply delineated border.[15,17]

Neoatheroma was defined as the combination of neointimal diffuse thickening with atherosclerotic plaque architectural features,[10] including lipid-laden intima and the presence of a fibrous cap.[5,11,12] Neointimal rupture was a break in the fibrous cap connecting the lumen with the underlying lipid pool.[12] Thrombi were masses protruding into the vessel lumen, discontinuous from the surface of the vessel wall and were characterized according to previous reports.[18] When attenuation, caused by large amounts of red thrombus, obscured underlying neointima morphology, intra-stent neoatherosclerosis containing lipid-laden neointima, and neointima rupture were identified as proximal or distal (or opposite) to the red thrombus.[12]

ISNA was recognized as the culprit lesion if the following criteria were fulfilled: (i) the presence of neoatherosclerotic tissue transformation within the stent; (ii) the presence of a neointimal rupture within

the stent; (iii) the absence of uncovered struts; (iv) the absence of ruptured-cap atherosclerotic lesion proximal or distal to the stent.

Follow-up

The patients included in the study were prospectively followed-up regarding adverse cardiovascular events. The clinical follow-up was carried out in clinic visits and/or through phone contact with all patients after hospital discharge. Cardiovascular adverse events were defined as cardiovascular death, non-fatal stroke, non-fatal myocardial infarction, and the need for urgent target vessel revascularization.

Statistical analysis

Statistical analysis was performed with SPSS 16.0 (SPSS software, Chicago, IL, USA) software. Data are expressed as the mean and standard error to the mean and the normality of their distribution was assessed by the Kolmogorov–Smirnov test. Categorical and continuous variables were compared using χ^2 or Fisher's exact tests and Mann–Whitney *U*-tests, respectively. Quantitative variables with non-normal distribution were log-transformed and univariate correlations were assessed by Spearman's rho test. A two-sided alpha level of 0.05 was used for all superiority testing.

Results

A total of 2139 patients with ACSs were admitted to both centres between October 2010 and November 2012. Twenty of these subjects (0.93%) presented a definite VLST. OCT imaging identified 10 subjects (50%) with evidence of ISNA lesions rupture without stent malapposition (*Figure 1*), whereas 10 patients had evidence of stent malapposition and/or incomplete neointimal coverage (non-ISNA group). There was full agreement between the two operators regarding VLST as the underlying cause.

Clinical and lesion characteristics for each of the ISNA patients are provided in *Table 1*. Eighty per cent of the patients were male and STEMI was the initial clinical presentation in half of the cases. BMS were implanted in 80% of the cases and first generation DES in 20%. Ninety per cent of the subjects reported pre-infarction angina in the days before the acute event. The mean delay between index PCI and VLST ranged from 1.3 to 17.5 years

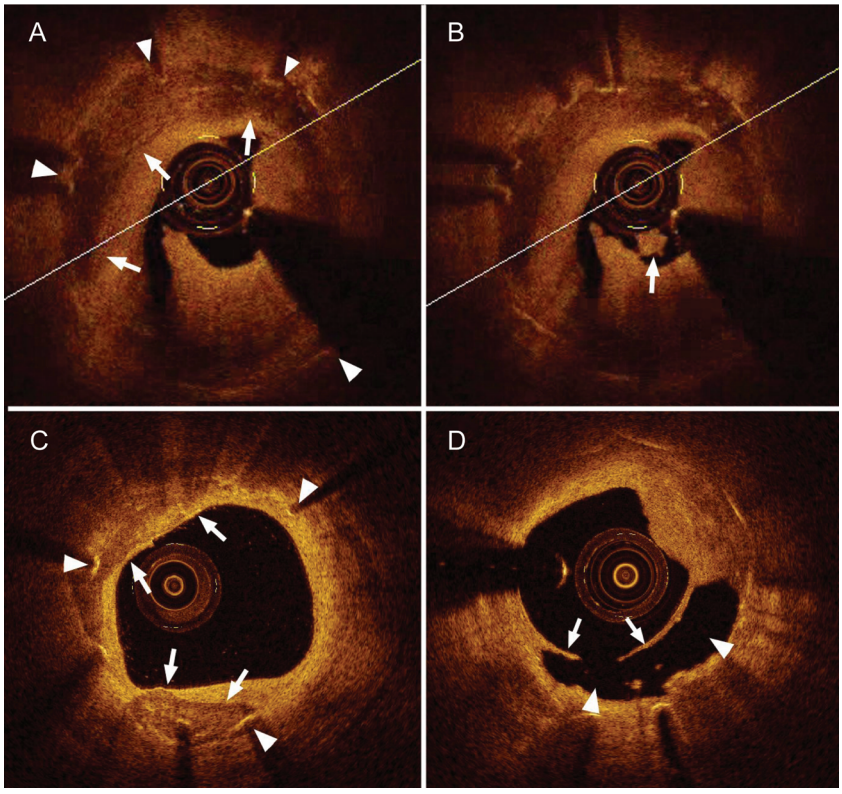

Figure 1 Examples of neoatherosclerosis related to VLST explored by OCT imaging with different timings. Case 1 (Patient #2; *A* and *B*): immediate intra-stent OCT analysis after successful manual thrombectomy. The images depicted the presence of heterogeneous tissue proliferation within the stent, lipid-laden intima with diffuse border, hypo-intense zones due to signal attenuation (*A*, white arrows) within the SA (delimited by the white arrowheads). No uncovered strut was seen but the presence of residual white thrombus was observed (*B*, white arrows). Case 2 (Patient #6; *C* and *D*): Deferred (15 days) OCT analysis after initial successful manual thrombectomy and initial antithrombotic therapy (abciximab + clopidogrel + aspirin). Two individualized thin fibrous cap lesions (*C*, white arrows) with lipidic content are visible among the thick neointimal proliferation within the SA (arrowheads). A ruptured fibrous cap was observed proximally (*D*, white arrows) connecting the lumen with the deterged core of the lesion (arrowheads).

Table 1 Characteristics of ISNA patients

Patient	Gender	Age (years)	ACS type	Culprit lesion location	In. PCI–VLST delay (years)	Stent	LDL-cholesterol (g/L)	APT at time of VLST	Ref. vessel diam. (mm)	Mean ISCSA	Thrombus type	Treatment option
Patient #1	Male	51.9	NSTEMI	LAD	3.7	DES Cypher©	1.54	Asp. + Clop.	4	5.74 ± 0.32	White	DES
Patient #2	Male	51.2	NSTEMI	LAD	6.1	DES Cypher©	1.3	Clop.	2.77	7.96 ± 0.91	White	DES
Patient #3	Male	74.3	STEMI	LAD	16.3	BMS Freedom©	1.15	Asp.	3.32	9.94 ± 0.92	Red	DES
Patient #4	Male	76.8	NSTEMI	LAD	13.0	BMS Wiktor©	1.12	None	3.3	9.73 ± 1.25	Red	BMS
Patient #5	Male	62.8	STEMI	RCA	5.5	BMS Flyer©	1.08	Asp.	3.5	10.9 ± 0.86	White	Balloon
Patient #6	Male	50.0	STEMI	LAD	14.1	BMS AVE©	1.16	None	3.5	7.03 ± 0.95	White	DES
Patient #7	Female	65.0	STEMI	RCA	15.2	BMS Wiktor©	2.34	Asp.	3.1	6.11 ± 0.87	White	DES
Patient #8	Male	53.2	NSTEMI	RCA	7.0	BMS Vision©	1.1	None	3.0	3.15 ± 0.89	White	DES
Patient #9	Female	71.8	STEMI	RCA	7.0	BMS Flyer©	1.1	Asp.	3.0	4.88 ± 0.79	Red	DES
Patient #10	Male	61.0	STEMI	Circumflex	17.5	BMS Wiktor©	0.65	Asp.	3.5	8.25 ± 030	White	DES

ACS, acute coronary syndrome; APT, anti-platelet therapy; Asp., Aspirin; AVE, AVE GFX; BMS, bare-metal stent; Clop., clopidogrel; Cypher, Cordis Cypher; DES, drug-eluting stent; Freedom: Global Therapeutics Freedom; Flyer, Atrium Flyer; In. PCI–VLST delay, index PCI to VLST delay; ISCSA, intra-stent cross-sectional area; LAD, left anterior descending artery; NSTEMI, non-ST elevation myocardial infarction; RCA, right coronary artery; STEMI, ST segment elevation myocardial infarction; VLST, very late stent thrombosis; Vision, Guidant Vision; Wiktor, Medtronic Wiktor.

(mean = 7.5 ± 1.1 years), highlighting the fact that VLST can occur >10 years after the initial procedure. Although most of the patients were taking aspirin and/or clopidogrel, 30% were under no APT at the time of the thrombotic event.

The comparison between the characteristics of patients from the two VLST groups is given in *Tables 2* and *3*. We observed that the delay between the initial PCI and the thrombotic event was longer in ISNA patients than non-ISNA patients. Interestingly,

Table 2 Comparison of clinical and biological baseline characteristics in VLST groups

	ISNA (*n* = 10)	Non-ISNA (*n* = 10)	*P*-value
Age (years)	61.7 ± 3.2	62.1 ± 5.2	0.96
Male gender, *n* (%)	8 (80)	8 (80)	1.0
STEMI, *n* (%)	6 (60)	8 (80)	0.63
Delay initial PCI–VLST (years)	10.5 ± 1.6	4.0 ± 0.6	0.003
Cardiovascular risk factors			
Current smoking, *n* (%)	3 (30)	3 (30)	1.0
Hypertension, *n* (%)	8 (80)	6 (60)	0.63
Diabetes, *n* (%)	2 (20)	2 (20)	1.0
Dyslipidaemia, *n* (%)	10 (100)	6 (60)	0.04
Body mass index, kg/m^2	26.3 ± 0.8	27.4 ± 1.5	0.54
Current medications at the time of event			
No APT, *n* (%)	3 (30)	5 (50)	0.65
Aspirin alone, *n* (%)	5 (50)	2 (20)	0.35
Clopidogrel alone, *n* (%)	1 (10)	3 (30)	0.58
Aspirin + Clopidogrel, *n* (%)	1 (10)	0	1.0
Statin therapy, *n* (%)	10 (100)	9 (90)	1.0
Biological characteristics			
CPK peak (IU/L)	2353 ± 841	2759 ± 780	0.72
LDL-cholesterol (mg/mL)	1.22 ± 0.14	0.94 ± 0.11	0.12
LDL-cholesterol>1.0 mg/mL, *n* (%)	9 (90)	4 (40)	0.02

APT, anti-platelet therapy; CPK, creatine phosphokinase; PCI, percutaneous coronary intervention; STEMI, ST elevation myocardial infarction.

Table 3 Angiographic and OCT features in VLST groups

	ISNA (*n* = 10)	Non-ISNA (*n* = 10)	*P*-value
Culprit lesion localization			
LAD, *n* (%)	5 (50)	6 (60)	1.0
RCA, *n* (%)	4 (40)	3 (30)	1.0
Circumflex, *n* (%)	1 (10)	0	1.0
Venous graft, *n* (%)	0	1 (10)	1.0
Stent baseline characteristics			
BMS, *n* (%)	8 (80)	4 (40)	0.09
First-generation DES, *n* (%)	2 (20)	5 (50)	0.65
Second-generation DES, *n* (%)	0	1 (10)	1.0
Stent diameter (mm)	3.3 ± 0.1	3.1 ± 0.1	0.32
Stent length (mm)	15.7 ± 1.4	19.8 ± 1.5	0.06
Angiographic characteristics			
Initial QCA (%)	95.6 ± 3.4	96.8 ± 3.2	0.81
Initial TIMI flow	0.3 ± 0.2	0.7 ± 0.4	0.38
Presence of collateral vessels, *n* (%)	7 (70)	1 (10)	0.02
Rentrop grade	1.3 ± 0.4	0.1 ± 0.1	0.01
Post-thrombectomy QCA (%)	76.4 ± 3.6	43.1 ± 7.1	0.01

Table 4 OCT features in VLST groups

	ISNA (n = 10)	Non-ISNA (n = 10)	P-value
Number of analysed struts	1145	2249	—
Number of struts analysed per cross section	6.0 ± 0.7	9.9 ± 0.7	<0.001
Number of struts analysed per lesion	114.5 ± 13.3	249.9 ± 25.7	<0.001
Lesion length (mm)	15.7 ± 1.4	19.8 ± 1.5	0.06
Average intra-stent lumen area (mm^2)	4.4 ± 0.6	6.3 ± 0.8	0.09
Minimal intra-stent lumen area (mm^2)	2.5 ± 0.7	5.1 ± 0.6	0.006
Average stent area (mm^2)	7.4 ± 0.9	7.0 ± 0.8	0.73
Minimal stent area (mm^2)	5.8 ± 0.9	6.3 ± 0.8	0.68
Average neointima area (mm^2)	3.3 ± 0.4	0.9 ± 0.1	<0.001
Percentage of uncovered struts	0	31.5 ± 4.4	<0.001
White thrombus, n (%)	7 (70)	6 (60)	1.0
Red thrombus, n (%)	3 (30)	4 (40)	1.0
Homogeneous intima tissue, n (%)	0	6 (60)	0.11
Heterogeneous intima tissue, n (%)	10 (100)	4 (40)	0.11
Presence of intimal vessels, n (%)	6 (60)	2 (20)	0.17
Presence of calcifications, n (%)	7 (70)	3 (30)	0.07

we observed among patients with ISNA, a trend towards a shorter delay in patients with DES compared with BMS (4.9 ± 1.2 vs. 11.9 ± 1.6 years, $P = 0.08$). Furthermore, a history of dyslipidaemia was more frequent in the ISNA group and the mean baseline LDL-cholesterol value tended to be higher compared with the other group. There was no significant difference between the two groups regarding clinical presentation, APT regimen, stent type, or culprit lesion localization; however, we observed that the initial angiographic Rentrop grade was higher in the ISNA patients compared with the non-ISNA patients, suggesting a more progressive phenomenon. Finally, the degree of post-thrombectomy residual stenosis (as measured by QCA) was higher in the ISNA group than in the non-ISNA group.

OCT measurements analysed $n = 3394$ struts (*Table 4*). We observed that the minimal intra-stent luminal area was significantly smaller in the ISNA group compared with the non-ISNA group, but there was no significant difference in minimal and average SA values among all patients. Furthermore, the average neointima area and neointima thickness per strut were significantly higher in the ISNA patients compared with the others. Finally, we observed a significant correlation between the average neointima area and LDL-cholesterol levels (Spearman's rho = 0.46, $P = 0.04$; *Figure 2*).

OCT analysis allowed us to provide the most appropriate therapy, according to VLST aetiology. All ISNA patients except one were treated with stent implantation within the original device. A DES was used in 90% of cases and one patient received a BMS because of a high-bleeding risk and contraindications for long-term dual APT. Among non-ISNA patients, a subsequent intra-stent non-compliant balloon angioplasty was performed in five patients and medical therapy alone was proposed in five patients.

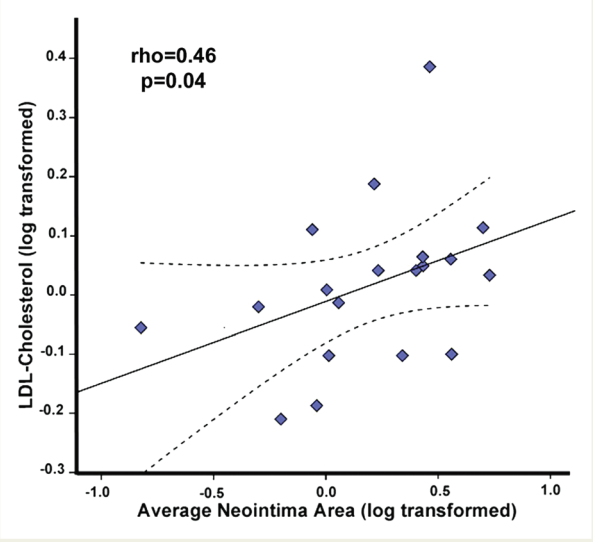

Figure 2 Correlation between LDL-cholesterol and average neointima area. Both variables were log-transformed due to their non-normal distribution in the study population.

The clinical follow-up was successfully carried out in all patients (follow-up median time: 261 days/inter-quartile range: 203 days). One patient from the non-ISNA group died, from a fatal ventricular arrhythmia (control angiography revealed no stent thrombosis) 15 days after the initial STEMI. There was no major cardiovascular adverse event during the hospital-phase or after hospital discharge for the ISNA patients, suggesting that the treatment of these lesions with repeated stenting could represent an appropriate option.

Discussion

In this study, OCT imaging identified ISNA in half of the patients with VLST presenting as ACS. The present data illustrate that this phenomenon: (i) is frequent among VLST; (ii) can occur in both BMS and DES; and (iii) can occur very late after index PCI.

Although VLST is a rare and uncommon complication of PCI, its consequences are severe and its pathophysiology is not fully understood. The presence of incomplete neointimal coverage has been identified as a major risk factor for stent thrombosis, including VLST.[7,19] The uncovered struts favour platelet adhesion and facilitate the local clotting process.[7] Other factors are suspected to be potential risk factors for LST and VLST, such as stenting of highly necrotic plaques, presence of a disrupted plaque or residual dissection <2 mm from stent extremities.[7] Recently, autopsy and intra-coronary imaging data (including intra-vascular ultrasound, OCT or angioscopy) have identified the presence of neoatherosclerosis lesions within previously implanted DES and BMS.[3,5,12,20] These lesions displayed plaque architecture with a lipid core, a fibrous cap and neovascularization[5] as well as peristrut inflammatory cell infiltration.[3] Regarding this data, the potential involvement of ISNA plaque rupture in VLST pathophysiology has been questioned.

Hence, Kang *et al.*[12] analysed patients presenting with ACS related to DES restenosis using OCT imaging and observed thin fibrous cap rupture and thrombi in >75% of cases. Interestingly, the percentage of thin-cap rupture and the presence of thrombi increased over time and was higher in the DES implanted longer than 20 months compared with those implanted <20 months.[12] However, this series excluded patients with angiographically proven stent thrombosis, which might have led to an underestimation of the true incidence of the phenomenon. Furthermore, Yamaji *et al.*[21] identified 42 cases of BMS VLST and observed the presence of atherosclerosis debris (foamy macrophages, cholesterol crystal, fibrous cap) after manual thrombo-aspiration in 31% of cases, but in 39% of the patients with VLST occurring over 3 years after initial PCI. Comparable results were observed by Hou *et al.*[11] who identified ruptured ISNA lesions in one-third of their patients with ACS due to BMS restenosis. Overall, these data suggest that ISNA is an entity with true involvement in DES and BMS failure, and thereby contributes to LST and VLST. In the present series based on 'real-world' patients with definite VLST according to ARC criteria, ISNA was observed in 50% of the cases, which is consistent with previous results.

The mechanisms underlying ISNA formation are not yet clear. Inoue *et al.*[22] reported that arteries exhibited endothelial coverage with smooth muscle cells and collagen-rich neointima that was infiltrated with inflammatory cells, 2–3 years after BMS implantation. This chronic inflammation occurred around the struts and evolved over time: in stents that had been in place >4 years, smooth muscle cells were sparse, with abundant collagen and evidence of foamy macrophages (expressing metalloproteinases).[22] Nakazawa *et al.*[3] made similar observations in both BMS and DES and suggested that the phenomenon progressed differently according to stent type: the lesion progression was faster in vessels treated with DES than in those treated with BMS. Interestingly, despite the limited size of our sample, we observed that the delay between index PCI and VLST tended to be shorter in ISNA patients with DES compared with those with BMS. All these results suggest that neointima formation occurring within metallic stent implants is prone to the same atherosclerotic phenomenon as that affecting native vessels. Whereas this phenomenon usually evolves over a period of 40 years in native vessels,[23] our study showed a faster progression within the implanted stents (as witnessed by the delay ranging from 3 to 16 years after the initial procedure). The underlying chronic inflammation related to the presence of the stent could hasten neoatherosclerosis plaque formation and its evolution towards rupture. The observation of an 'accelerated' ISNA formation within DES compared with BMS has to be confirmed, but might be the result of an aggravated local inflammatory reaction or hypersensitivity related to the presence of the polymer or cytostatic drug.[24–26] The regenerated endothelium present at the surface of the stent might also possibly be dysfunctional and favour the migration of lipids and inflammatory cells within the neointima, which would enhance ISNA formation.[27] Interestingly, we have also noted that all our ISNA VLST patients still had LDL-cholesterol levels above the recommended target levels,[28] suggesting that persistent hypercholesterolaemia despite statin therapy could, thus, have impacted ISNA pathogenesis. This latter hypothesis was also supported by the positive correlation we observed between the average neointima area and LDL-cholesterol values in our study population, but will need a larger group of patients to confirm this. Finally, these findings highlight the need for improved control of cardiovascular risk factors in secondary prevention situations.

Several limitations of the study warrant consideration. First, our results are based on data collected from two catheterization centres and the sample size is small. This limited sample is related to the low frequency of VLST in the ACS population and our inclusion criteria, which only focused on angiographically proven definite VLST in both BMS and DES. Therefore, we might have underestimated the frequency of the phenomenon in the general population and the true incidence of ISNA within stents might be different. Our data might, thus, differ from the previously published results obtained in pathology specimens,[3] in unstable patients without definite stent thrombosis[12] or the results observed in thrombo-aspiration products without the use of any intra-vascular coronary imaging.[21] The present series completes and broadens our knowledge of the topic by providing information through the analysis of an unselected group of patients. Nonetheless, further research in larger multicentre samples is warranted to comprehensively investigate the incidence, mechanisms, and risk factors of ISNA. The present data were collected by OCT analysis. Although this technique has an excellent spatial resolution and is appropriate for the detection of thin-cap fibroatheroma,[14] it also has some drawbacks, including the signal attenuation caused by large amounts of red thrombus or very thick neointima that might obscure the underlying neointima morphology or stent struts. Hence, previous studies reported that thick neointima could result in an intra-stent multilayered aspect during the OCT analysis.[29] These properties might explain why fewer struts were visualized in the ISNA patients (another possible explanation relies on the longer stent length in the non-ISNA group). Finally, our imaging analysis was not corroborated by the pathological

analysis of thrombo-aspiration debris, since this procedure was not routinely performed in our two centres.

In summary, the current study shows that ISNA is frequent in an unselected population of ACS patients presenting with VLST. Furthermore, our data provide new insights on ISNA pathogenesis, as it shows a longer interval of occurrence from the index procedure to events in neoatherosclerosis compared with non-ISNA VLST, as well as a poorer control of dyslipidaemia in the ISNA subjects. Overall, these results suggest that OCT imaging is useful to: (i) identify the mechanisms underlying VLST; and (ii) help in the clinical decision-making process and lead to the optimal treatment of subjects with this complication (i.e. redo stenting in case of ISNA rupture vs. thrombectomy-antithrombotic management in non-ISNA patients). This particular point has to be investigated in future larger randomized trials.

Conflict of interest: N.A., G.S., C.C., and P.M. received consulting fees from St Jude Medical. P.M. received consulting fees from Terumo.

References

1. Schatz RA, Palmaz JC, Tio FO, Garcia F, Garcia O, Reuter SR. Balloon-expandable intracoronary stents in the adult dog. *Circulation* 1987;**76**:450–7.
2. Weintraub WS. The pathophysiology and burden of restenosis. *Am J Cardiol* 2007;**100**(Supp. 5):S3–9.
3. Nakazawa G, Otsuka F, Nakano M, Vorpahl M, Yazdani SK, Ladich E *et al.* The pathology of neoatherosclerosis in human coronary implants: bare-metal and drug-eluting stents. *J Am Coll Cardiol* 2011;**57**:1314–22.
4. Takano M, Yamamoto M, Mizuno M, Murakami D, Inami T, Kimata N *et al.* Late vascular responses from 2 to 4 years after implantation of sirolimus-eluting stents: serial observations by intracoronary optical coherence tomography. *Circ Cardiovasc Interv* 2010;**3**:476–83.
5. Takano M, Yamamoto M, Inami S, Murakami D, Ohba T, Seino Y *et al.* Appearance of lipid-laden intima and neovascularization after implantation of bare-metal stents extended late-phase observation by intracoronary optical coherence tomography. *J Am Coll Cardiol* 2010;**55**:26–32.
6. Cutlip DE, Windecker S, Mehran R, Boam A, Cohen DJ, van Es G-A *et al.* Clinical end points in coronary stent trials. *Circulation* 2007;**115**:2344–51.
7. Farb A, Burke AP, Kolodgie FD, Virmani R. Pathological mechanisms of fatal late coronary stent thrombosis in humans. *Circulation* 2003;**108**:1701–6.
8. Finn AV, Otsuka F. Neoatherosclerosis: a culprit in very late stent thrombosis. *Circ Cardiovasc Interv* 2012;**5**:6–9.
9. Gutierrez-Chico JL, Alegria-Barrero E, Teijeiro-Mestre R, Chan PH, Tsujioka H, de Silva R *et al.* Optical coherence tomography: from research to practice. *Eur Heart J Cardiovasc Imaging* 2012;**13**:370–84.
10. Yabushita H, Bouma BE, Houser SL, Aretz HT, Jang IK, Schlendorf KH *et al.* Characterization of human atherosclerosis by optical coherence tomography. *Circulation* 2002;**106**:1640–5.
11. Hou J, Qi H, Zhang M, Ma L, Liu H, Han Z *et al.* Development of lipid-rich plaque inside bare metal stent: possible mechanism of late stent thrombosis? An optical coherence tomography study. *Heart* 2010;**96**:1187–90.
12. Kang SJ, Mintz GS, Akasaka T, Park DW, Lee JY, Kim WJ *et al.* Optical coherence tomographic analysis of in-stent neoatherosclerosis after drug-eluting stent implantation. *Circulation* 2011;**123**:2954–63.
13. Authors/Task Force M, Van de Werf F, Bax J, Betriu A, Blomstrom-Lundqvist C, Crea F *et al.* Management of acute myocardial infarction in patients presenting with persistent ST-segment elevation: the Task Force on the management of ST-segment elevation acute myocardial infarction of the European Society of Cardiology. *Eur Heart J* 2008;**29**:2909–45.
14. Rentrop KP, Cohen M, Blanke H, Phillips RA. Changes in collateral channel filling immediately after controlled coronary artery occlusion by an angioplasty balloon in human subjects. *J Am Coll Cardiol* 1985;**5**:587–92.
15. Prati F, Guagliumi G, Mintz GS, Costa M, Regar E, Akasaka T *et al.* Expert review document part 2: methodology, terminology and clinical applications of optical coherence tomography for the assessment of interventional procedures. *Eur Heart J* 2012;**33**:2513–2520.
16. Gutierrez-Chico JL, Regar E, Nuesch E, Okamura T, Wykrzykowska J, di Mario C *et al.* Delayed coverage in malapposed and side-branch struts with respect to well-apposed struts in drug-eluting stents/clinical perspective. *Circulation* 2011;**124**:612–23.
17. Tearney GJ, Regar E, Akasaka T, Adriaenssens T, Barlis P, Bezerra HG *et al.* Consensus standards for acquisition, measurement, and reporting of intravascular optical coherence tomography studies: a report from the international working group for intravascular optical coherence tomography standardization and validation. *J Am Coll Cardiol* 2012;**59**:1058–72.
18. Prati F, Regar E, Mintz GS, Arbustini E, Di Mario C, Jang IK *et al.* Expert review document on methodology, terminology, and clinical applications of optical coherence tomography: physical principles, methodology of image acquisition, and clinical application for assessment of coronary arteries and atherosclerosis. *Eur Heart J* 2010;**31**:401–15.
19. Guagliumi G, Sirbu V, Musumeci G, Gerber R, Biondi-Zoccai G, Ikejima H *et al.* Examination of the *in vivo* mechanisms of late drug-eluting stent thrombosis: findings from optical coherence tomography and intravascular ultrasound imaging. *JACC: Cardiovasc Interv* 2012;**5**:12–20.
20. Higo T, Ueda Y, Oyabu J, Okada K, Nishio M, Hirata A *et al.* Atherosclerotic and thrombogenic neointima formed over sirolimus drug-eluting stent: an angioscopic study. *JACC: Cardiovasc Imaging* 2009;**2**:616–24.
21. Yamaji K, Inoue K, Nakahashi T, Noguchi M, Domei T, Hyodo M *et al.* Bare metal stent thrombosis and in-stent neoatherosclerosis. *Circ Cardiovas Interv* 2012;**5**:47–54.
22. Inoue K, Abe K, Ando K, Shirai S, Nishiyama K, Nakanishi M *et al.* Pathological analyses of long-term intracoronary Palmaz-Schatz stenting; is its efficacy permanent? *Cardiovasc Pathol* 2004;**13**:109–15.
23. Libby P, Ridker PM, Hansson GK. Progress and challenges in translating the biology of atherosclerosis. *Nature* 2011;**473**:317–25.
24. Inoue T, Croce K, Morooka T, Sakuma M, Node K, Simon DI. Vascular inflammation and repair: implications for re-endothelialization, restenosis, and stent thrombosis. *J Am Coll Cardiol Intv* 2011;**4**:1057–66.
25. Virmani R, Guagliumi G, Farb A, Musumeci G, Grieco N, Motta T *et al.* Localized hypersensitivity and late coronary thrombosis secondary to a sirolimus-eluting stent. *Circulation* 2004;**109**:701–5.
26. Stampfl U, Radeleff B, Sommer C, Stampfl S, Lopez-Benitez R, Thierjung H *et al.* Paclitaxel-induced arterial wall toxicity and inflammation: Part 2 long-term tissue response in a minipig model. *J Vasc Interv Radiol* 2009;**20**:1608–16.
27. Nakazawa G, Vorpahl M, Finn AV, Narula J, Virmani R. One step forward and two steps back with drug-eluting-stents: from preventing restenosis to causing late thrombosis and nouveau atherosclerosis. *JACC Cardiovasc Imaging* 2009;**2**:625–8.
28. Reiner Z, Catapano AL, De Backer G, Graham I, Taskinen MR, Wiklund O *et al.* ESC/EAS guidelines for the management of dyslipidaemias: the Task Force for the management of dyslipidaemias of the European Society of Cardiology (ESC) and the European Atherosclerosis Society (EAS). *Eur Heart J* 2011;**32**:1769–818.
29. Tanaka N, Terashima M, Rathore S, Itoh T, Habara M, Nasu K *et al.* Different patterns of vascular response between patients with or without diabetes mellitus after drug-eluting stent implantation: optical coherence tomographic analysis. *JACC Cardiovasc Interv* 2010;**3**:1074–79.